JOURNAL HEALTH AND TECHNOLOGY - JHT
ISSN 2764-7625

NARROW AND EXTRA-NARROW IMPLANTS TO RETAIN MANDIBULAR OVERDENTURES: A SPLIT-MOUTH STUDY

USO DE IMPLANTES ESTREITOS E EXTRA ESTREITOS PARA RETER SOBREDENTADURAS MANDIBULARES: UM ESTUDO DE BOCA DIVIDIDA

IMPLANTES ESTRECHOS Y EXTRAESTRECHOS PARA RETENER SOBREDENTADURAS MANDIBULARES: UN ESTUDIO DE BOCA DIVIDIDA

Sidney Sato Oku[1], Elisa Mattias Sartori[2], Francine Baldin Able[3], Fabiano Marcelo Nava[4], Guilherme José Pimentel Lopes Oliveira[5], Ivete Aparecida de Mattias Sartori[6]

e2128
https://doi.org/10.47820/jht.v2i1.28

RECEIVED: 12/15/2022 APPROVED: 01/15/2023 PUBLISHED: 01/25/2023

ABSTRACT
The aim of this study was to evaluate the primary and secondary stability and success rates of narrow and extra-narrow implants as retainers' mandibular overdentures. Twelve fully edentulous mandible patients participated of this split-mouth randomized controlled clinical trial. One narrow (Group 1: 3.5-mm) and one extra-narrow implant (Group 2: 2.9-mm) were placed in each patient. Data regarding anesthetics use, incision size, number of drills used, and surgery duration were obtained. Moreover, a satisfaction VAS (visual analog scale) questionnaire was answered by the surgeon to evaluate clinician satisfaction with respect to characteristics of the surgical procedure. The implants stability quotient (ISQ) was measured immediately after the implants placement (T0) and after four months of the surgical procedure (T4). Additionally, the success rates of the implants during the osseointegration period were recorded. Regarding the characteristics of the surgical technique, statistically significant difference between groups was found for incision length - which was significantly smaller for group G2 - and insertion torque - which was significantly greater for group G1 (P-value = 0.025 and 0.005, respectively). There was no statistically significant difference for ISQ values between T0 and T4 within the same group (G1, p=0.510 and G2, p=0.116). The implant success rate was 100% for both groups. Therefore, narrow, and extra-narrow implants showed good primary and secondary stability, as well as short-term implant success rates, without statistically significant differences between them, and thus seem to be suitable alternatives to retain immediately loaded mandibular overdentures.

KEYWORDS: Implant-supported prosthesis. Immediate loading. Narrow implants. Overdenture.

RESUMO
O objetivo deste estudo foi avaliar a estabilidade primária e secundária, e as taxas de sucesso de implantes estreitos e extra-estreitos como retentores de *overdentures* mandibulares. Doze pacientes com a mandíbula totalmente edêntula participaram deste ensaio clínico randomizado controlado de boca dividida. Um implante estreito (G1: 3.5 mm) e um extra-estreito (G2: 2.9 mm) foram instalados em cada paciente. Dados sobre o uso de anestésicos, tamanho da incisão, número de brocas usadas e duração da cirurgia foram obtidos. Um questionário de escala visual analógica de satisfação foi

[1] Student in Faculty ILAPEO, Department of Implantology, Curitiba, PR, Brazil. Master in Dentistry with concentration area in Implantology, Faculty ILAPEO, Curitiba, PR, Brazil.
[2] Professor in Faculty ILAPEO, Department of Implantology, Curitiba, PR, Brazil. PhD in Dentistry with concentration area in Oral and Maxillofacial Surgery, UNESP Araçatuba, SP, Brazil.
[3] Professor in Faculty Sete Lagoas, FACSETE, Belo Horizonte, MG, Brazil. PhD in Dentistry with concentration area in Integrated Clinic, UEPG, Ponta Grossa, PR, Brazil.
[4] Student in Faculty ILAPEO, Department of Implantology, Faculty ILAPEO, Curitiba, PR, Brazil. Master in Dentistry with concentration area in Implantology, Faculty ILAPEO, Curitiba, PR, Brazil.
[5] Associate Professor, Department of Periodontology and Implantology, Dentistry School, Federal University of Uberlandia, MG, Brazil. PhD in Dentistry with concentration area in Diagnosis and Surgery, UNESP Araraquara, SP, Brazil.
[6] Professor in Faculty ILAPEO, Department of Implantology, Curitiba, PR, Brazil. PhD in Oral Rehabilitation, USP Ribeirão Preto, SP, Brazil.

JOURNAL HEALTH AND TECHNOLOGY - JHT
ISSN 2764-7625

respondido pelo cirurgião para avaliar a satisfação do clínico com relação às características do procedimento cirúrgico. O ISQ foi medido imediatamente após a instalação dos implantes (T0) e após quatro meses (T4). As taxas de sucesso dos implantes durante o período de osseointegração foram registradas. Em relação às características da técnica cirúrgica, houve diferença estatisticamente significativa entre os grupos quanto ao comprimento da incisão - significativamente menor no grupo G2 - e torque de inserção - significativamente maior no grupo G1 (P-value = 0.025 e 0.005, respectivamente). Não houve diferença estatisticamente significativa para os valores de ISQ entre T0 e T4 dentro do mesmo grupo (G1, p=0.510 e G2, p=0.116). A taxa de sucesso dos implantes foi de 100% para ambos os grupos. Portanto, implantes estreitos e extra-estreitos apresentaram boa estabilidade primária e secundária, bem como taxas de sucesso de implantes a curto prazo, sem diferenças estatisticamente significativas entre eles, e assim parecem ser alternativas adequadas para reterem *overdentures* mandibulares em carga imediata.

PALAVRAS-CHAVE: Prótese implantossuportada. Carga imediata. Implantes estreitos. Overdenture.

RESUMEN
El objetivo de este estudio fue evaluar la estabilidad primaria y secundaria y las tasas de éxito de los implantes estrechos y extraestrechos como sobredentaduras mandibulares de retenedores. Doce pacientes con mandíbula completamente edéntula participaron en este ensayo clínico controlado aleatorio de boca dividida. Se colocó un implante estrecho (G1: 3,5 mm) y uno extraestrecho (G2: 2,9 mm) en cada paciente. Se obtuvieron datos sobre el uso de anestésicos, el tamaño de la incisión, el número de taladros utilizados y la duración de la cirugía. Además, el cirujano respondió un cuestionario de satisfacción VAS (escala analógica visual) para evaluar la satisfacción del clínico con respecto a las características del procedimiento quirúrgico. El cociente de estabilidad de los implantes (ISQ) se midió inmediatamente después de la colocación de los implantes (T0) y después de cuatro meses del procedimiento quirúrgico (T4). Además, se registraron las tasas de éxito de los implantes durante el período de osteointegración. En cuanto a las características de la técnica quirúrgica, se encontró diferencia estadísticamente significativa entre los grupos para la longitud de la incisión - que fue significativamente menor para el grupo G2 - y el par de inserción - que fue significativamente mayor para el grupo G1 (valor de p = 0,025 y 0,005, respectivamente). No hubo diferencia estadísticamente significativa para los valores de ISQ entre T0 y T4 dentro del mismo grupo (G1, p = 0,510 y G2, p = 0,116). La tasa de éxito del implante fue del 100% para ambos grupos. Por lo tanto, los implantes estrechos y extraestrechos presentaron buena estabilidad primaria y secundaria, así como tasas de éxito de implantes a corto plazo, sin diferencias estadísticamente significativas entre ellos, y por lo tanto parecen ser alternativas adecuadas para retener las sobredentaduras mandibulares en carga inmediata.

PALABRAS CLAVE: Implantprótesis soportadas. Carga inmediata. Implantes estrechos. Sobredentadura.

INTRODUCTION

Despite the health advances that have allowed reduction of tooth loss worldwide[1], the prevalence of fully edentulous patients is still high [2,3]. Although fully edentulous patients were the first to benefit from rehabilitation with dental implants, it still represents a major challenge in implant dentistry[4]. Due to long periods of an edentulous condition and the use of complete dentures, it is not uncommon for these patients to present severe resorptions of the alveolar bone that require the use of bone grafting techniques to promote increased bone availability for dental implants placement [5].

However, certain clinical conditions can impair the execution of the regenerative procedures in totally edentulous patients. Severe atrophies of the alveolar process require regenerative techniques

JOURNAL HEALTH AND TECHNOLOGY - JHT
ISSN 2764-7625

associated with the use of autogenous bone graft [6], which despite being the gold standard for guided bone regenerative procedures, presents limitations in relation to donor bed morbidity and limited availability of this type of graft [7]. These limitations could be inadequate for elderly patients, who are usually the ones to suffer most with total edentulism [8]. Thus, the use of more conservative surgical techniques should be preferably indicated [9].

The narrow implants were developed to make the rehabilitation of regions with limited space, such as lower incisors and upper lateral incisors, possible [10,11]. Therefore, these implants have shown to be predictable in this type of rehabilitation, obtaining good aesthetic results, avoiding the use of bone grafting techniques [12,13]. Because of good clinical outcomes and high survival and success rates, the narrow implants have been used in other cases such as single-unit rehabilitation in the posterior regions of maxilla and mandible [14,15], in implant supported full-arch rehabilitation [16] and in overdenture rehabilitation [17,18].

One of the limitations reported due to the use of the narrow implants is the achievement of primary stability for early-load, especially in overdenture prostheses, due to the smaller number of implants that usually support them [19], however, little has been discussed about that. Therefore, the aim of this study was to evaluate the primary and secondary stability of narrow (3.5-mm) and extra-narrow (2.9-mm) implants, supporting immediately loaded overdentures prostheses and the short-term (4 months) success rates of these implants after the osseointegration period.

THEORETICAL FRAMEWORK

The search for conservative surgical procedures with reduced patient morbidity has been a trend in medicine and dentistry [9]. Specifically in implantology, efforts have been made to perform less invasive procedures to promote an adequate restoration of the masticatory function [20,21]. In fully edentulous patients with limited bone thickness, the use of overdenture prosthesis retained by two implants provides oral rehabilitation with minimal morbidity. Moreover, mandibular overdentures have been reported to improve patients' quality of life, by reducing issues related to conventional dentures such as instability, inability to grind food and decreased self-confidence [18,22].

METHOD

Study design

The research project was approved by the Ethical Committee of the Evangelical Beneficent Society (Curitiba, Brazil; protocol number - 621 514). All the procedures were conducted according to the Helsinki declaration and written consent was given by all patients. Patients with the following inclusion criteria were included in the study: good systemic health, and enough bone to enable the placement of implants with 3.5mm diameter and at least 11 mm length, confirmed by panoramic and lateral cephalometric radiograph or CT scan, when necessary. Also, the patients had to be wearing their removable dentures regularly. Uncontrolled diabetes, smoking, use of bisphosphonate drugs, head and

neck irradiation in the past five years as well as those who were not wearing their lower removable dentures were not included.

The hypothesis of comparable procedures between the two implants regarding time required for surgical installation, incision size and clinician satisfaction, was tested performing a split-mouth randomized controlled clinical trial. Each patient received two types of implants: Group 1 (G1) consisted of 3.5-mm diameter implants (Titamax Cortical Cone Morse, Neodent, Curitiba, Brazil) and group 2 (G2) consisted of 2.9-mm diameter implants (Morse Taper Facility, Neodent, Curitiba, Brazil).

Presurgical procedures

The mandibular prostheses received gutta percha markers, 11 mm equidistant from the midline, with a total distance of 22 mm between marks (Figure 1). Then, panoramic (Figure 2) and lateral cephalometric radiographs were obtained for the planning of the optimum position for implant placement. Once the optimum distances were established, the removable prostheses were perforated so that they could be used as surgical guides (Figure 3). Afterwards, these were disinfected with 2% chlorhexidine gluconate.



Figure 1. Front view of the prosthesis with gutta percha markers in place



Figure 2. Orthopantomogram panoramic radiograph. Note the image of gutta percha markers.

JOURNAL HEALTH AND TECHNOLOGY - JHT
ISSN 2764-7625



Figure 3. Occlusal aspect of the perforated prosthesis.

Surgical procedures

Before the surgical procedure, the patients have mouth washed for one-minute with a 0.12% chlorhexidine digluconate (Noplak Max, Rio de Janeiro, Brazil). An infiltrative anesthesia (Mepiadre 100, DFL, Rio de Janeiro, Brazil) was then carried out and the perforated removable prosthesis was placed, and the implant position was marked using gentian violet.

Implants of both groups were placed in the same surgical procedure and followed the recommended drilling sequence, aiming to achieve enough primary stability to allow immediate loading.

The implant driver was used at a motor speed of 30rpm until insertion torque of 35 Ncm. When stability was achieved, the torque wrench was used to complete the installation.

The Abutment Selection Kit (Neodent, Curitiba, Brazil) was used to select the height of the abutments, 1 to 2mm above the soft tissue level. Group 1 received Equator Attachment Abutments (Neodent, Curitiba, Brazil) that were inserted with torque of 32 N.cm, using a torque wrench (Neodent, Curitiba, Brazil) whereas frictional Equator Attachment Abutments (Neodent, Curitiba, Brazil) were used in Group 2. Three hits were performed in these abutments with the surgical hammer (Neodent, Curitiba, Brazil) that controlled the load applied during insertion. The abutments for both groups were specially designed to present internal threads that allow the insertion of a stability measuring device. Each flap was sutured with nylon thread 5-0 (Bioline, Anápolis, Brazil).

The patients were instructed about oral hygiene procedures. Antibiotics and anti-inflammatory medications were prescribed (Amoxicillin 875 mg every 12 hours for 7 days and Ibuprofen 600 mg every 12 hours for 3 days). The sutures were removed 7 to 10 days after surgery. Patients were instructed to

schedule evaluation appointments in case of pain, difficulty in insertion or removal of the prosthesis or any other complication. All surgical procedures were performed by the same operator.

Prosthetic procedures

To capture O-rings with cylinders, protection disks (Figure 4) and retention components were placed in the mouth. The prosthesis was positioned and, in cases where misadaptation was observed, adjustments were performed until its adaptation. The capture of both components was carried out simultaneously using chemical polymerization acrylic resin (LS Pattern Resin, Illinois, USA) (Figure 5 and 6). Finishing and polishing procedures were carried out using a drill kit for finishing and polishing Acrylic Resin (aluminum oxide and silicon resin) (EVE, Pforzheim, Germany).



Figure 4. Buccal view of the equator abutments inserted with protection discs in order to capture the components in the prosthesis.



Figure 5. Occlusal view of dentures with the captured retaining components.

JOURNAL HEALTH AND TECHNOLOGY - JHT
ISSN 2764-7625

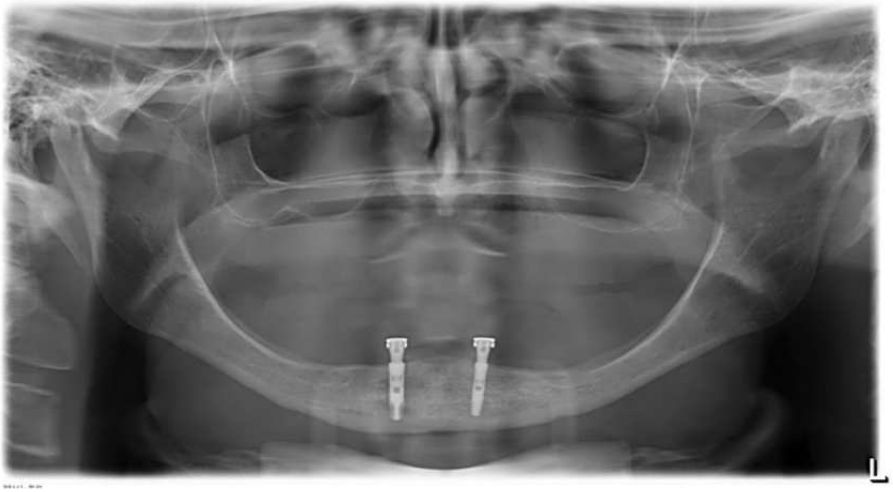

Figure 6. Orthopantomogram panoramic radiograph after 4 months. Right side with 3.5mm diameter implant (G1) and left side with 2.9mm diameter implant (G2).

Data analysis

Data regarding anesthetics use, incision length, number of drills used, surgery duration and final insertion torque were obtained. Moreover, a satisfaction VAS (visual analog scale) questionnaire was answered by the surgeon to evaluate each implant individually regarding safety, implants placement, suture, surgical technique and general outcomes of the rehabilitation.

An Osstell device (Osseointegration Diagnosis, Gothenburg, Sweden) was used to measure the implant stability quotient (ISQ). The SmartPeg A3 model (Osstell, Gothenburg, Sweden) was inserted within the Equator Attachment (Neodent, Curitiba, Brazil). ISQ measurements were carried out in three different directions (buccal, mesial and distal) and performed immediately after implants placement (T0) and at the 4-month follow-up (T4).

Implants without pain and inflammation during the follow-up period were considered successful at T4. Follow-up panoramic radiographs were obtained for all patients at this stage (Figure 1F).

Statistical analysis

The Kolmogorov-Smirnov test was used to analyze the distribution of the variables. Quantitative variables were analyzed using the Student-T test or Wilcoxon test to compare baseline values with 4-month values. P values <0.05 were considered statistically significant. Data were analyzed using the software IBM SPSS v.20.0 (Armonk, USA).

RESULTS AND DISCUSSION

Twenty-Four implants were placed in twelve edentulous patients (6 male and 6 female) with a mean age of 65 years and 8 months (ranging from 48 to 84 years). Twelve implants were evaluated for each group. In one patient, the minimal initial stability for immediate loading was not achieved by both

implants, therefore the flap was sutured, and no load was applied during the osseointegration period. These implants were excluded from ISQ analysis. All other implants were immediately load.

The results regarding clinician satisfaction are shown in Table 1. No statistically significant difference was found between groups for any of the parameters evaluated by the questionnaire.

Table 1. VAS values for the questions used to evaluate clinician satisfaction according to group.

Questions/Group	G1	G2	p
	Mean ± S.D.	Mean ± S.D.	
Drilling Safety (0-10)	7.9 ± 1.2	8.3 ± 0.6	0.402
Implants placement (0-10)	7.4 ± 1.4	8.1 ± 0.5	0.155
Suture (0-10)	8.2 ± 0.7	8.4 ± 0.8	0.310
Surgical technique (0-10)	7.3 ± 2.4	8.3 ± 0.8	0.260
General satisfaction (0-10)	7.3 ± 1.9	8.2 ± 0.8	0.314

The intergroup analysis is shown in Table 2. Statistically significant difference between groups was found for incision length – which was significantly smaller for group G2 – and insertion torque –

which was significantly greater for group G1 ($p = 0.025$ and 0.005, respectively). The ISQ mean values for the two groups at T0 and T4 showed no statistically significant difference (0.219 and 0.260). The intragroup analysis (Table 3) showed no statistically significant difference for ISQ values between T0 and T4 within the same group (G1, $p=0.510$ and G2, $p=0.116$).

Table 2. Student-t test for intergroup analysis of clinical parameters.

Clinical Parameters/Group	G1	G2	p
	Mean ± S.D.	Mean ± S.D.	
Number of Anesthetics (tubes)	1.9± 0.5	1.7 ± 0.3	0.139
Incision length (mm)	13.5 ± 3.3	11.6 ± 3.1	0.025*
Number of drills used	4.3 ± 1.1	3.5 ± 0.8	0.155
Surgery duration (Minutes)	21.95 ± 13.74	16.68 ± 3.43	0.272
Insertion Torque (N.cm)	56.8 ± 18.4	44.8 ± 11.7	0.005*
ISQ T0	66.36 ± 5.25	63.27 ± 5.36	0.219
ISQ T4	73.45 ± 4.63	71.12 ± 4.22	0.260

*Statistically significant at $p < 0.05$

JOURNAL HEALTH AND TECHNOLOGY - JHT
ISSN 2764-7625

Table 3. Student-t test for intragroup analysis of ISQ values at T0 and T4.

Group	Time	Mean ISQ ±S.D.	p
G1	T0	66,36±5.25	
	T4	65,36±6.80	
	Difference	-1,00±4.86	0,510
G2	T0	63,27±5.36	
	T4	60,15±6.81	
	Difference	-3,12±6.01	0,116

The clinical analysis of both groups after four months found that there were no clinical signs of pain and/or inflammation. None of the patients reported pain when the implants were individually evaluated. Thus, the success rate of the implants in both groups was 100% after 4 months of follow-up.

In G2, one Equator Attachment Abutment had to be replaced. Regarding the characteristics of the surgical technique, data were more favorable for G2, since incision size was significant smaller for G2 (p=0.025), and it presented good stability that allowed immediate loading. However, the primary stability was significant higher in G1 (p=0.012).

The intragroup analysis showed no statistically significant difference for ISQ values between T0 and T4 within the same group (G1, p=0.510 and G2, p=0.116).

Thus, extra-narrow and narrow implants presented excellent primary stability. Although 3.5 mm-diameter implants presented a significantly higher final insertion torque, both groups achieved the minimum stability required for immediate loading [23] except for one patient which prosthesis was installed after 6 months. Regarding ISQ, narrow implants presented higher values than extra-narrow implants, both at the time of placement (T0) and 4 months thereafter (T4), corroborating with other studies that have reported a correlation between implant diameter and higher ISQ, especially for cylindrical implants[24]. However, no statistical significance was found between groups and mean optimal values were achieved for both implant diameters. With respect to intragroup secondary stability, it was possible to observe that ISQ values at T4 were slightly higher than T0, for both groups, as reported by other authors [24,25], whereas other studies have reported that they tend to decrease over time [23,26].

In addition, the protocol applied in this study proved to be safe since there was no loss of implants in up to 4 months after implants placement. Indeed, the safety for the use of the immediate loading protocol under narrow-implants was also found in previous clinical studies [27,28]. Therefore, it seems that overdentures retained by reduced diameter implants are a reliable alternative to avoid bone grafts, being less invasive and reducing treatment time and costs, which leads to greater patient satisfaction and quality of life [19].

In general, the surgeon seemed to be very satisfied regarding the surgical procedure of narrow and extra-narrow implants, as all parameters evaluated by the VAS questionnaire achieved high values

for both groups. Due to the reduced diameter, there is a reduction in the number of drills used and surgery time. Moreover, it was observed that flaps required for 2.9-mm implants were significantly smaller than the flaps opened for 3.5-mm implants, which might result in faster wound healing and, consequently, higher patient satisfaction. In fact, previous clinical studies have shown that patients who are submitted to the insertion of narrow implants reported high satisfaction with aesthetics and function, and would recommend the surgical procedure [18].

However, the present outcomes suggest that the application of immediate loading in narrow and extra-narrow implants to support mandibular overdentures did not negatively interfere with implants success rates in this critical phase. The same has been reported by other authors, with 90% of implant survival rate for mandibular overdenture [23] and 99.4% for single-unit rehabilitation with immediately loaded narrow implants [29].

CONSIDERATIONS

This study presents some drawbacks that must be considered when interpreting the data presented. This short-term study evaluated only the clinical behavior of the narrow-implants during the osseointegration phase, which limits whether these good clinical outcomes found at a four-month period after the surgical procedure will be maintained for longer periods of follow-up. In addition, the small sample size of this study reduces its clinical significance, and further investigations with a bigger sample size should be performed. Thus, within the limitations of this study, it is possible to conclude that the narrow implants with 2.9 mm and 3.5 mm narrow implants presented good primary and secondary stability without statistical differences between them., both types of narrow implants supported well the immediate loading of mandibular overdentures.

REFERENCES

1. Kassebaum NJ, et al. Global Burden of Severe Tooth Loss: A Systematic Review and Meta-analysis. J. Dent. Res. 2014;93:20S-28S.

2. Hewlett SA, et al. Prevalence and geographic distribution of edentulism among older Ghanaians. J. Public Health Dent. 2015;75:74–83.

3. Peltzer K, et al. Prevalence of loss of all teeth (edentulism) and associated factors in older adults in China, Ghana, India, Mexico, Russia and South Africa. Int. J. Environ. Res. Public Health. 2014;11:11308–11324.

4. Oliveir, LB de, Gabrielli MAC, Gabrielli MFR, Pereira-Filho VAP. Implant-supported rehabilitation after treatment of atrophic mandibular fractures: report of two cases. Oral Maxillofac. Surg. 2015;19:427–431.

5. Qiu L, Yu H. Onlay grafting with bovine bone mineral block for horizontal reconstruction of severely atrophic alveolar ridges in anterior maxillae: A 6-year prospective study. J. cranio-maxillo-facial Surg. Off. Publ. Eur. Assoc. Cranio-Maxillo-Facial Surg. 2018;46:1199–1204.

6. Chappuis V, Cavusoglu Y, Buser D, Von Arx T. Lateral Ridge Augmentation Using Autogenous Block Grafts and Guided Bone Regeneration: A 10-Year Prospective Case Series Study. Clin. Implant Dent. Relat. Res. 2017;19:85–96.

7. Monje A, et al. Horizontal Bone Augmentation Using Autogenous Block Grafts and Particulate Xenograft in the Severe Atrophic Maxillary Anterior Ridges: A Cone-Beam Computerized Tomography Case Series. J. Oral Implantol. 2015;41(Spec No):366–371.

8. Cano-Gutiérrez C, Borda MG, Arciniegas AJ, Borda CX. Edentulism and dental prostheses in the elderly: impact on quality of life measured with EuroQol--visual analog scale (EQ-VAS). Acta Odontol. Latinoam. 2015;28:149–155.

9. Pommer B, et al. Trends in techniques to avoid bone augmentation surgery: Application of short implants, narrow-diameter implants and guided surgery. J. Cranio-Maxillofacial Surg. 2016;44:1630–1634.

10. Galindo-Moreno P, et al. Clinical and radiographic evaluation of early loaded narrow diameter implants - 1-year follow-up. Clin. Oral Implants Res. 2012;23:609–616.

11. Kolinski M. et al. Immediate provisionalization in the esthetic zone: 1-year interim results from a prospective single-cohort multicenter study evaluating 3.0-mm-diameter tapered implants. Clin. Oral Investig. 2018;22:2299–2308.

12. Badran Z, et al. Clinical Performance of Narrow-Diameter Titanium-Zirconium Implants: A Systematic Review. Implant Dent. 2017;26:316–323.

13. Moráguez O, Vailati F, Grütte L, Sailer I, Belser UC. Four-unit fixed dental prostheses replacing the maxillary incisors supported by two narrow-diameter implants – a five-year case series. Clin. Oral Implants Res. 2017;28:887–892.

14. de Souza AB, et al. Narrow- and regular-diameter implants in the posterior region of the jaws to support single crowns: A 3-year split-mouth randomized clinical trial. Clin. Oral Implants Res. 2018;29:100–107.

15. Shi J.-Y. *et al.* Long-term outcomes of narrow diameter implants in posterior jaws: A retrospective study with at least 8-year follow-up. Clin. Oral Implants Res. 2018;29:76–81.

16. Artzi Z. *et al.* The efficacy of full-arch immediately restored implant-supported reconstructions in extraction and healed sites: a 36-month retrospective evaluation. Int. J. Oral Maxillofac. Implants. 2010;25:329–335.

17. Marcello-Machado RM, et al. One-year clinical outcomes of locking taper Equator attachments retaining mandibular overdentures to narrow diameter implants. Clin. Implant Dent. Relat. Res. 2018;20:483–492.

18. Reissmann DR, et al. Long-term changes in oral health-related quality of life over a period of 5 years in patients treated with narrow diameter implants: A prospective clinical study. J. Dent. 2018;75:84–90.

19. Schuster AJ, et al. Short-term quality of life change perceived by patients after transition to mandibular overdentures. Braz. Oral Res. 2017;31:e5.

JOURNAL HEALTH AND TECHNOLOGY - JHT
ISSN 2764-7625

20. Froum SJ, Shi Y, Fisselier F, Cho S-C. Long-Term Retrospective Evaluation of Success of Narrow-Diameter Implants in Esthetic Areas: A Consecutive Case Series with 3 to 14 Years Follow-up. Int. J. Periodontics Restorative Dent. 2017;37:629–637.

21. Marcello-Machado RM, Faot F, Schuster AJ, Nascimento GG, Del Bel Cury AA. Mini-implants and narrow diameter implants as mandibular overdenture retainers: A systematic review and meta-analysis of clinical and radiographic outcomes. J. Oral Rehabil. 2018;45:161–183.

22. Policastro VB, et al. A Randomized Clinical Trial of Oral Health-Related Quality of Life, Peri-Implant and Kinesiograph Parameters in Wearers of One-or Two-Implant Mandibular Overdentures. J. Prosthodont. Off. J. Am. Coll. Prosthodont. 2019;28:757–765.

23. Bielemann AM, et al. Healing differences in narrow diameter implants submitted to immediate and conventional loading in mandibular overdentures: A randomized clinical trial. J. Periodontal Res. 2019;54:241–250.

24. Aragoneses JM, Aragoneses J, Brugal VA, Gomez M, Suarez A. Relationshipbetween implant length and implant stability of single-implant restorations: A 12-month follow-up clinical study. Med. 2020;56:1–11.

25. Tanaka K, et al. Relationship between cortical bone thickness and implant stability at the time of surgery and secondary stability after osseointegration measured using resonance frequency analysis. J. Periodontal Implant Sci. 2018;48:360–372.

26. Turkyilmaz I, McGlumphy E.A. Influence of bone density on implant stability parameters and implant success: A retrospective clinical study. BMC Oral Health. 2008;8:1–8.

27. Giannakopoulos NN, et al. Immediate and delayed loading of two-piece reduced-diameter implants with locator-analog attachments in edentulous mandibles: One-year results from a randomized clinical trial examining clinical outcome and patient expectation. Clin. Implant Dent. Relat. Res. 2017;19:643–653.

28. Worni A, Hicklin SP, Mericske-Stern R, Enkling N. Performance and marginal bone level alteration around immediately loaded narrow-diameter implants. A prospective clinical study: Results after 1 year. Quintessence Int. 2018;49:267–276.

29. Degidi M, Piattelli A, Carinci F. Clinical Outcome of Narrow Diameter Implants: A Retrospective Study of 510 Implants. J. Periodontol. 2008;79:49–54.